

Giant hepatic hemangioma with Kasabach-Merritt syndrome treated with right hepatectomy: a case report with literature review

Bhavin Vasavada^{A-F} , *Hardik Patel*^{D-E} 

Department of Hepatobiliary and Liver Transplant Surgery, Shalby Hospitals, Ahmedabad, India

A – Research concept and design, B – Collection and/or assembly of data, C – Data analysis and interpretation, D – Writing the article, E – Critical revision of the article, F – Final approval of the article

Abstract

Background: We present a case of giant hepatic hemangioma with Kasabach-Merritt syndrome.

Material and methods: A thirty-seven-year-old female presented to us with a six-month history of recurrent abdominal pain and weight loss. A CT scan was suggestive of a huge right liver mass involving the entire right lobe, which was indicative of hemangioma. Her blood chemistry showed a platelet count of 68,000 and INR of 1.4, suggestive of Kasabach-Merritt syndrome.

Results: In view of the size of the mass, symptoms and associated Kasabach-Merritt syndrome, the patient was offered surgical removal of the tumour. On exploration, the tumour covered the right lobe completely and so a right hepatectomy was performed. The hemangioma was 25 cm × 20 cm × 16 cm and weighed 1.8 kg. The postoperative course of the patient was uneventful. On day 3, the platelet count had improved to 98,000 and the INR had improved to 1.2. The patient was discharged on day five.

Conclusions: A right hepatectomy for a giant hemangioma of the liver is a safe procedure and can be curative for associated Kasabach-Merritt syndrome.

Keywords: Giant hemangioma, liver tumours, right hepatectomy

Introduction

Hepatic hemangiomas are the most common benign liver tumours with prevalence ranging from 1% to 20% and seen predominantly in women. In adults, hemangiomas are usually found in patients at a mean age of 50 years and equally in the left and right lobes of the liver. Most hemangiomas are small in size and do not cause any symptoms and therefore do not require any treatment [1–4]. Small hemangiomas are usually less than 3 cm in size and medium hemangiomas are usually between 3 cm to 10 cm in size. Hemangiomas measuring more than 10 cm are known as giant hepatic hemangiomas. Hepatic hemangiomas are usually discovered accidentally, or they cause symptoms. Most of them have typical radiologic features.

✉ Bhavin Vasavada, email: drbhavin.liversurgeon@gmail.com

Giant hepatic hemangiomas usually present with symptoms. Kasabach-Merritt syndrome consists of a giant hepatic hemangioma with coagulopathy and thrombocytopenia [5]. Patients with a giant hepatic hemangioma usually require surgery for the symptoms. The symptoms resolve soon after surgery. In most cases Kasabach-Merritt syndrome also resolves after surgery.

We report the case of a giant liver hemangioma of 25 cm and 1.8 kg in weight presenting with symptoms such as abdominal pain, weight loss and associated Kasabach-Merritt syndrome.

Case report

A 37-year-old female presented to us with a six-month history of recurrent abdominal pain and weight loss. On examination, a large hypochondrial mass, which moved on respiration and suggested a liver mass, was discovered. Ultrasound showed a large right hepatic mass. A CT scan found a huge right liver mass involving the entire right lobe, with peripheral nodular enhancement and progressive centripetal fill-in, suggestive of hemangioma, while the rest of the liver was non cirrhotic with a normal spleen and no signs suggestive of portal hypertension. Her blood chemistry showed a platelet count of 68,000 and INR of 1.4, indicative of Kasabach-Merritt syndrome.

In view of the size of the mass, symptoms and associated Kasabach-Merritt syndrome, the patient was offered surgical removal of the tumour. On exploration, the tumour entirely covered the right lobe, so the decision to perform a right hepatectomy was taken. The liver was mobilized and a portal dissection was performed. The right hepatic artery, right portal vein and right bile duct were dissected and looped. The right hepatic artery and right portal vein were clamped, and the transection line was marked. The liver was transected under selective occlusion of the right portal vein and the right hepatic artery.

The right hepatic artery, right portal vein and right bile duct were doubly ligated and divided. The right hepatic vein was divided intrahepatically and the specimen was retrieved. The hemangioma was of 25 cm × 20 cm × 16 cm and weighed 1.8 kg. The histopathology confirmed a giant hemangioma.

The postoperative course of the patient was uneventful. On day 3 the platelet count was improved to 98,000 and the INR improved to 1.2. The patient was discharged on day five. There was not morbidity.

Discussion

Hepatic hemangiomas are congenital vascular malformations and the most common benign liver tumours [5]. They are most commonly seen in females in their fifth to sixth decade [1–4].

They are usually solitary tumours, but multiple tumours can also be seen. Malignant transformation is usually not seen.

The etiology of hepatic hemangioma is not clear, but most researchers suggest that they are congenital in origin and that patients have a genetic predisposition [5].

Hepatic hemangiomas are usually detected from imaging performed for other reasons or for vague abdominal symptoms. On ultrasound, hepatic hemangiomas appear as a hyper echoic nodule with a regular margin with posterior acoustic enhancement. On CT scans, they are seen as a hypodense, well-defined lesion, which after contrast injection shows peripheral nodular enhancement with progressive centripetal homogeneous filling. On MRI, the typical appearance is a well-demarcated, homogenous lesion, hypointense in T1-weighted images and hyperintense in T2-weighted images [5].

Giant hemangiomas may be asymptomatic or can present with abdominal pain and weight loss, as in our case. On rare occasions they attain a very large size of about 20 to 40 cm. Left lobe hemangiomas can present with pressure symptoms on adjacent organs, such as vomiting, anorexia and jaundice. In giant hemangiomas the symptoms are largely due to inflammation, or due to the consumptive coagulopathy of Kasabach-Merritt syndrome and compression of the adjacent organs [6].

Spontaneous rupture of hemangioma and hemoperitoneum is another potential complication which can be life-threatening.

Kasabach-Merritt syndrome includes Giant Hepatic hemangioma, thrombocytopenia, and coagulopathy [7]. This coagulopathy consists of intravascular coagulation, clotting, and fibrinolysis within the hemangioma, which was seen in our case. It can lead to spontaneous bleeding and rupture of the hemangioma, which can be life-threatening. Kasabach-Merritt syndrome usually disappears after removal of the hemangioma [8], which was also seen in the case under discussion and was suggested by improvement in the thrombocytopenia and prothrombin time and the international normalized ratio on post operative day four.

Whatever the size, there is no treatment for asymptomatic hemangioma. Indications for treatment include severe symptoms, complications, and inability to exclude malignancy [9,10].

Surgical resections remain the definitive treatment in symptomatic giant hemangioma with Kasabach-Merritt syndrome; other therapies such as hepatic artery ligation and radiation therapy are less effective [11,12].

In giant symptomatic hepatic hemangioma, the treatment usually indicated is surgical resection. Enucleation or formal anatomic resection depends upon the size and location of the tumour as well as technical skills. Peripheral located tumours should be enucleated and large tumours and deeply located tumours should be removed by formal anatomic resection, as was performed in the case reported here [13–17]. Right and Left hepatectomy should be performed whenever the hemangioma involves an entire lobe, as in the present case. Liver transplantation has also been used successfully to treat symptomatic patients with a technically unresectable, complicated giant hemangioma [17].

In conclusion right hepatectomy for a giant hemangioma of the liver is a safe procedure and can be curative for associated Kasabach-Merritt syndrome.

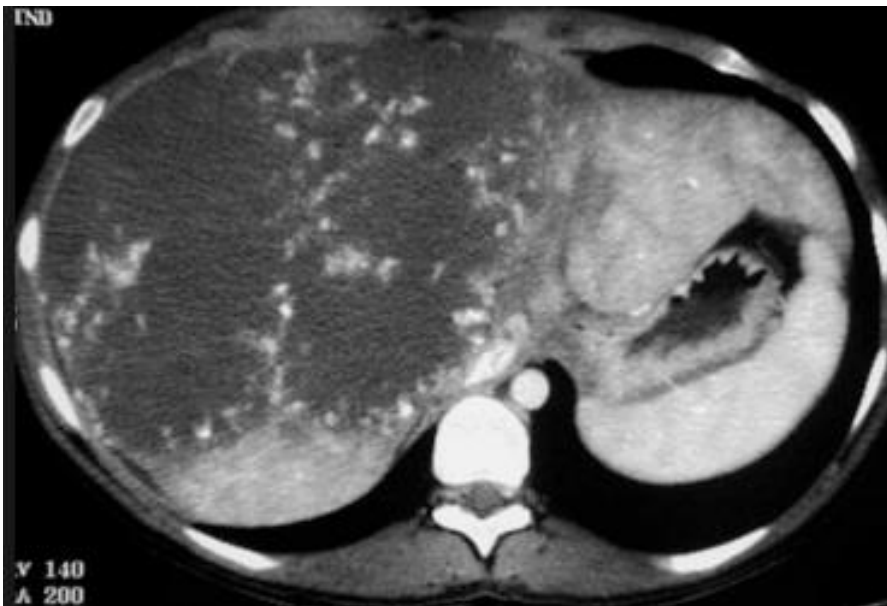


Figure 1. CT scan showing right liver hemangioma

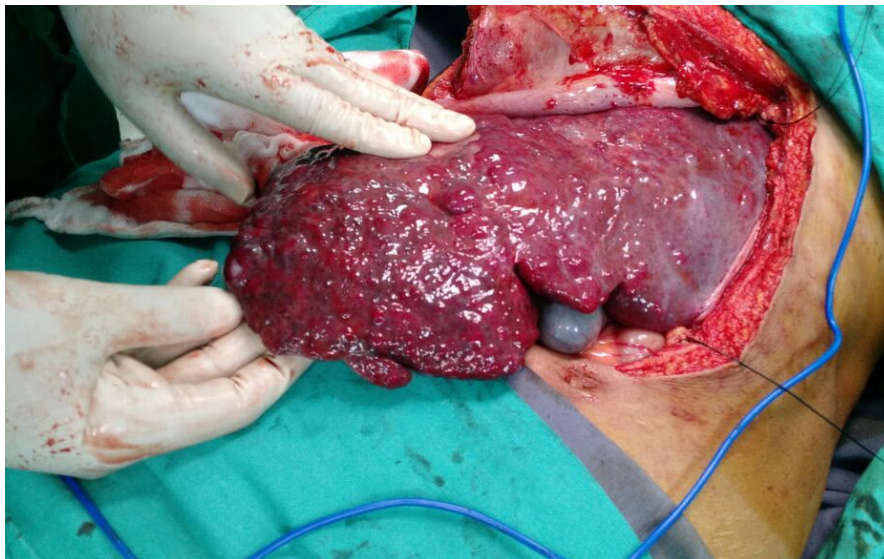


Figure 2. Intraoperative picture (Photo by Vasavada)

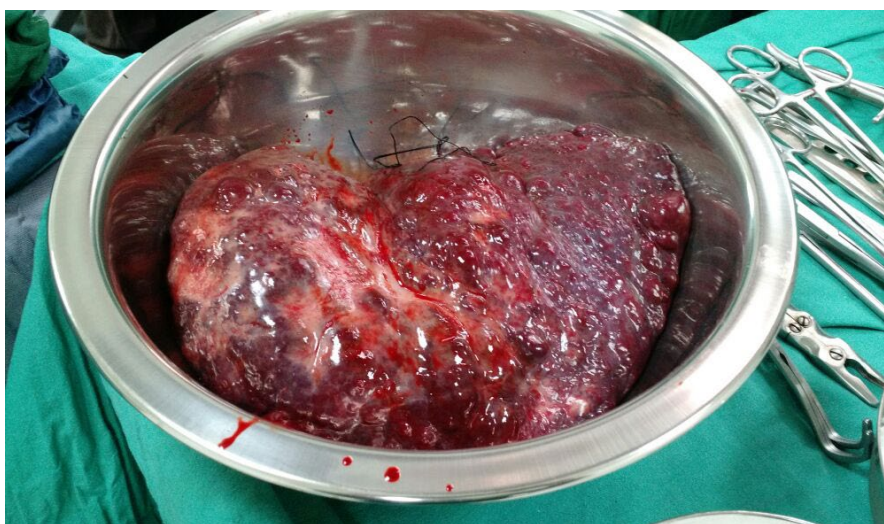

Figure 3. Specimen (Photo by Vasavada)

References

1. Semelka RC, Sofka CM. Hepatic hemangiomas. *Magn Reson Imaging Clin N Am.* 1997;5:241–253.
2. Mergo PJ, Ros PR. Benign lesions of the liver. *Radiol Clin North Am.* 1998;36:319–331.

3. Trotter JF, Everson GT. Benign focal lesions of the liver. *Clin Liver Dis.* 2001;5:17–42.
4. Biecker E, Fischer HP, Strunk H, Sauerbruch T. Benign hepatic tumours. *Z Gastroenterol.* 2003;41(2):191–200.
5. Losanoff JE, Millis JM. Liver hemangioma complicated by obstructive jaundice. *Am J Surg.* 2008;196:e3–44.
6. Hall GW. Kasabach-Merritt syndrome: pathogenesis and management. *Br J Haematol.* 2001;112:851–862.
7. Concejero AM, Chen CL, Chen TY, Eng HL, Kuo FY. Giant cavernous hemangioma of the liver with coagulopathy: adult Kasabach-Merritt syndrome. *Surgery.* 2009;145(2):245–247, <https://doi.org/10.1016/j.surg.2007.07.039>.
8. Duxbury MS, Garden OJ. Giant haemangioma of the liver: observation or resection? *Dig Surg.* 2010;27:7–11.
9. Yoon SS, Charny CK, Fong Y, Jarnagin WR, Schwartz LH, Blumgart LH, et al. Diagnosis, management, and outcomes of 115 patients with hepatic hemangioma. *J Am Coll Surg.* 2003;197(3):392–402.
10. Gaspar L, Mascarenhas F, da Costa MS, Dias JS, Afonso JG, Silvestre ME. Radiation therapy in the unresectable cavernous hemangioma of the liver. *Radiother Oncol.* 1993;29(1):45–50.
11. Reading NG, Forbes A, Nunnerley HB, Williams R. Hepatic haemangioma: a critical review of diagnosis and management. *Q J Med.* 1988;67(253):431–445.
12. Herman P, Costa ML, Machado MA, Pugliese V, D’Albuquerque LA, Machado MC, et al. Management of hepatic hemangiomas: a 14-year experience. *J Gastrointest Surg.* 2005;9(6):853–839.
13. Erdogan D, Busch OR, van Delden OM, Bennink RJ, ten Kate FJ, Gouma DJ, et al. Management of liver hemangiomas according to size and symptoms. *J Gastroenterol Hepatol.* 2007;22(11):1953–1958.
14. Kuo YT, Lin MB, Sheu RS, Liu GC, Chai CY, Chou SH. Imaging diagnosis of cavernous hemangioma of the rib – one case report and review of the literature. *Gaoxiong Yi Xue Ke Xue Za Zhi.* 1994;10(8):469–473.
15. Gedaly R, Pomposelli JJ, Pomfret EA, Lewis WD, Jenkins RL. Cavernous hemangioma of the liver: anatomic resection vs. enucleation. *Arch Surg.* 1999;134(4):407–411.
16. Fu XH, Lai EC, Yao XP, Chu KJ, Cheng SQ, Shen F, et al. Enucleation of liver hemangiomas: is there a difference in surgical outcomes for centrally or peripherally located lesions? *Am J Surg.* 2009;198(2):184–187.
17. Ercolani G, Grazi GL, Pinna AD. Liver transplantation for benign hepatic tumors: a systematic review. *Dig Surg.* 2010;27(1):68–75.