






Acute small bowel obstruction due to Quain hernia (caused by defect of broad ligament), diagnostic and treatment challenge

Stephan Raffener^{1,B-E} , *Esmeralda Eshja*^{2,B-C} , *Ruth Happacher*^{1,E} ,
Galyna Shabat^{1,A-F} , *Martin Mueller*^{1,F} 

1 Department of General Surgery, Hospital of Merano, Merano (Bolzano), Italy

2 Department of Radiology, Hospital of Merano, Merano (Bolzano), Italy

A – Research concept and design, B – Collection and/or assembly of data, C – Data analysis and interpretation, D – Writing the article, E – Critical revision of the article, F – Final approval of the article

Abstract

Background: Acute small bowel obstruction due to internal hernia is a rare condition. One of the most rare encounters is the Quain hernia (caused by broad ligament defect).

Material and methods: A rare case of internal Quain hernia due to a broad ligament defect that caused an acute small intestine obstruction is described.

Results: The challenge of diagnosis and the treatment choice is briefly discussed.

Conclusions: Patients with broad ligament defect could be clinically very challenging with not effective RX for the early diagnosis. CT scan with intravenous contrast enhancement could be useful for diagnosis and CT radiologic sign of deviation of the “healthy” uterus to the left or to the right side could be considered like an indirect CT sign of Quain internal hernia. More clinical case studies of treatment options are necessary for further evaluations.

Keywords: acute small bowel obstruction, internal hernia, broad ligament defect, surgery

Introduction

An acute small intestine obstruction due to internal hernia is a rare condition that occurs in around 0.6% to 6% of all small bowel obstructions [1]. Several rare types of hernia exist, including small bowel and epiploon, such as the Amyand, DeGarengeot and Littre types of hernia [2]. One of the rarest cases is that described in 1861 by Quain, discovered via autopsy, which was a case of hernia through the broad ligament. In 1934, Hunt classified three types of hernia through the broad ligament for the first time [1,3–6]. In 1986, an anatomical classification of broad ligament defects was proposed by Cilley et al. Type 1 defects occur caudal to the round ligament of the uterus, type 2 defects occur above the round ligament, while type 3 defects

✉ Galyna Shabat, email: galyna.shabat@gmail.com

occur between the round ligament and the remainder of the broad ligament, through the meso-ligamentum teres [3]. These cases of Quain hernia were manifested clinically with an acute small intestine obstruction [1,4].

Case description

Patient Presentation

We present the clinical case of a 52-year-old patient with an intestinal obstruction resulting from passage of part of the small intestine through a fenestration in the broad ligament of the uterus repaired by laparoscopic suturing with recurrence one year after surgery.

Before the first surgery, this was a clinical case of a 52-year-old female patient with no history of previous surgery, with abdominal pain history over eight years with multiple visits to the emergency care unit, family doctor and gastroenterologist, who never performed a colonoscopy or gastroscopy. Previous X-rays of the abdomen had not shown specific signs.

Diagnostic Workup

During evaluation at the emergency room, the patient presented typical symptoms of an acute small bowel obstruction with abdominal pain, nausea, vomiting more than ten times (food and after bile), pale and cold skin, warmer abdomen skin, meteorism, but no acute abdomen symptoms (Blumberg negative).

An X-ray of the abdomen showed moderate meteorically widened loops of the small intestine in the left middle and lower abdomen. There were no air fluid levels and there was no evidence of pneumoperitoneum. Blood tests showed a mild increase in inflammation indices (white blood cells, neutrophils, lactates).

A Computed Tomography (CT) scan showed dilation and distension of the intestinal loops, mainly ileal with multiple pathological hydroaeric levels, mostly in the central-abdominal area and in the lower abdomen, where a difference in the caliber of the loop in the left iliac fossa, specifically in the paramedian region, raised a suspicion of ileal volvulus. The appearance of the mesenteric venous vessels and some millimeter lymph nodes of the mesenterial root was congested. A small amount of free fluid was noted in the pelvis. Deviation of the uterus to the right-hand side was evident, which could suggest the presence of an internal hernia. CT conclusion: ileal volvulus, internal hernia, minimal free fluid at pelvis (Fig. 1) [7,8].

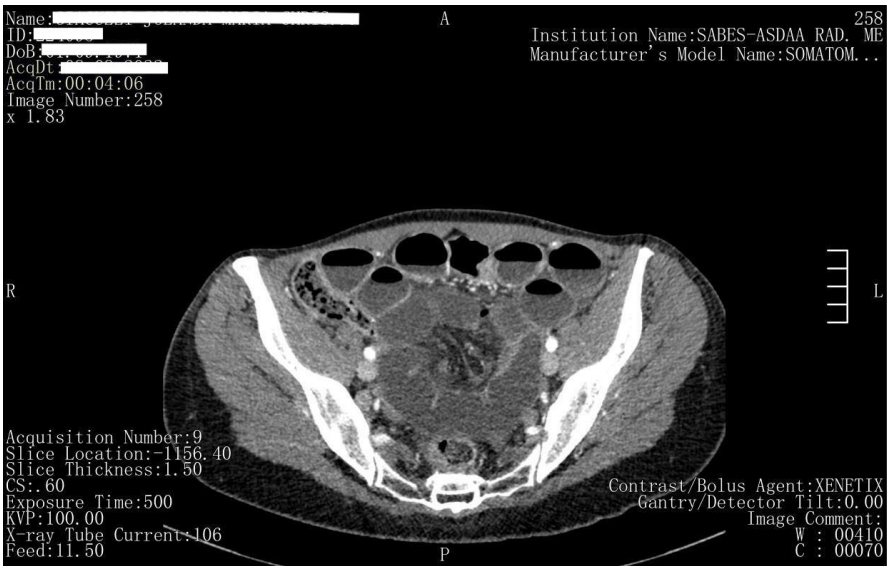

Figure 1. CT scan of the patient with an acute small intestine obstruction due to an internal hernia caused by broad ligament defect

Management

The patient recovered at the Surgical Department, received diagnostic laparoscopy, which clearly showed an internal hernia through a broad ligament defect with the small intestine still viable, which was preserved and the broad ligament defect was successfully repaired with laparoscopic non-absorbable surgical suturing (Fig. 2). The patient's position was supine, and the first optical trocar was inserted using an open technique, placed supraumbilically with a 10 mm diameter, while the other two work trocars (5 mm) were placed in the standard manner as for a left ovariectomy. There are two main concepts of broad ligament repair that have already been described and published: laparoscopic suture repair of the defect or salpingo-oophorectomy [9,10]. The decision was made to preserve the ovary and perform laparoscopic suturing with non-absorbable surgical suturing. The patient was successfully discharged from the hospital on the fourth postoperative day in good local and general health.

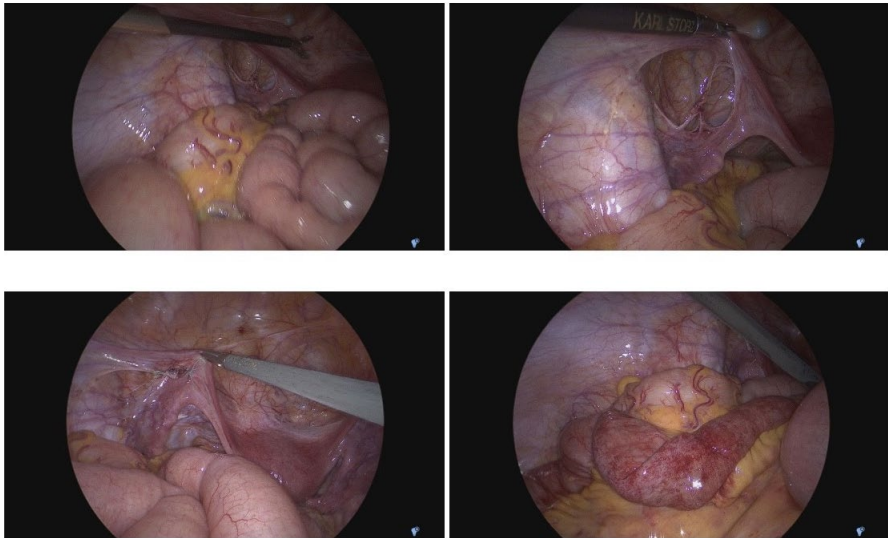


Figure 2. Laparoscopic diagnostic and laparoscopic broad ligament repair (suturing with non-absorbable surgical suture) for an acute small intestine obstruction caused by Quain internal hernia (photo by Shabat)

Follow up

Over one year the patient felt totally well and never came to the emergency department or gastroenterologist.

Management of recurrence

One year after laparoscopic suturing of the broad ligament defect the patient came back to the emergency room with clinical symptoms of an acute small bowel obstruction and acute abdomen. An X-ray of the abdomen confirmed a small intestine obstruction. A CT scan showed necrosis of the loop of the small intestine due to an internal hernia.

During laparotomy, 25 cm of small bowel was resected due to intestinal ischemic necrosis caused by a recurrent hernia in the remnant of the broad ligament. The patient was successfully discharged from the hospital on the seventh postoperative day in good local and general health.

Conclusion

Over a number of years patients with broad ligament defects could have clinical symptoms similar to irritable bowel disease.

An X-ray may not be useful for early precise diagnosis, but could be useful only in the case of evidence of a small intestine obstruction with air-fluid levels in the intestinal loops.

A CT scan with intravenous contrast enhancement could evidence radiological signs of deviation of the “healthy” uterus to the left or to the right side. This radiological sign could be important for the diagnosis of an internal hernia through broad ligament defect and could be considered an indirect CT sign of Quain internal hernia.

Laparoscopic suturing or resection should be evaluated as a treatment option and the best way forward needs to be discussed. More clinical case studies are necessary for further evaluations.

References

1. Ierardi K, Beffa L. Internal Hernia through Congenital Broad Ligament Defect. *ACS Case Reviews in Surgery*. 2018;2(2):50–53.
2. Akşedowski K, Komorowski AL, Bazieliç A, Sielski P. Strangulated epiploon in the inguinal canal as an atypical presentation of Amyand hernia. *Medicine and Public Health*. 2023;1(1):1–4, <https://doi.org/10.48269/MandPH-AFM-KU-23-1-005>.
3. Cilley R, Poterack K, Lemmer J, Dafoe D. Defects of the broad ligament of the uterus. *Am J Gastroenterol*. 1986;81(5):389–391.
4. Nandi P, Jain S, Kainth A, Atri S. Internal Hernia Through a Congenital Defect in Broad Ligament: A Rare and Elusive Cause of Intestinal Obstruction. *Cureus*. 2022;14(5):e24769, <https://doi.org/10.7759/cureus.24769>.
5. MacDonald S, Stokes E, Macdonald A, Sharaf U. Quain hernia – A rare cause of acute small bowel obstruction. A case report and an updated literature review. *Int J Surg Case Rep*. 2021;89:106599, <https://doi.org/10.1016/j.ijscr.2021.106599>.
6. Takahashi M, Yoshimitsu M, Yano T, Idani H, Shiozaki S, Okajima M. Rare Contents of an Internal Hernia through a Defect of the Broad Ligament of the Uterus. *Case Rep Surg*. 2021;2021:5535162, <https://doi.org/10.1155/2021/5535162>.
7. Barbier Brion B, Daragon C, Idelcadi O, Manton G, Kastler B, Delabrousse E. Small bowel obstruction due to broad ligament hernia: computed tomography findings. *Hernia*. 2011;15(3):353–355, <https://doi.org/10.1007/s10029-010-0660-5>.
8. Kubota W, Sakuma A, Katada R, Nagao T, Murota C. Usefulness of early diagnosis of small bowel obstruction due to broad ligament hernia using multidetector computed tomography: a case report. *J Surg Case Rep*. 2022;2022(1):rjab598, <https://doi.org/10.1093/jscr/rjab598>.
9. Marzouk M, Al Abdulsalam A, Soliman A. Bowel Obstruction Caused by Broad Ligament Hernia Successfully Repaired by Laparoscopy in an Elderly

Patient: A Case Report. *Cureus*. 2022;14(3):e23237, <https://doi.org/10.7759/cureus.23237>.

10. Toolabi K, Zamanian A, Parsaei R. Bowel obstruction caused by broad ligament hernia successfully repaired by laparoscopy. *Ann R Coll Surg Engl*. 2018;100(4):e94–e96, <https://doi.org/10.1308/rcsann.2018.0022>.